


.....

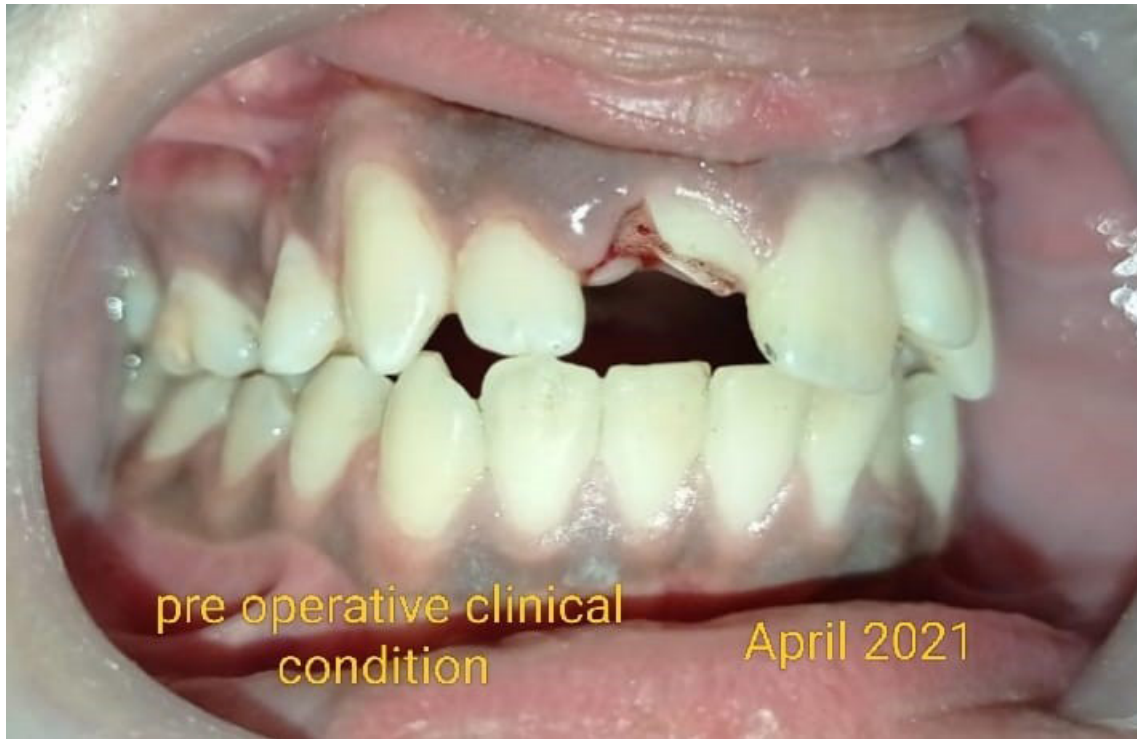GMI IMPLANT IMMEDIATELY AFTER EXTRACTION IN AESTHETIC ZONE WITH TEMPORARY CROWN

.....

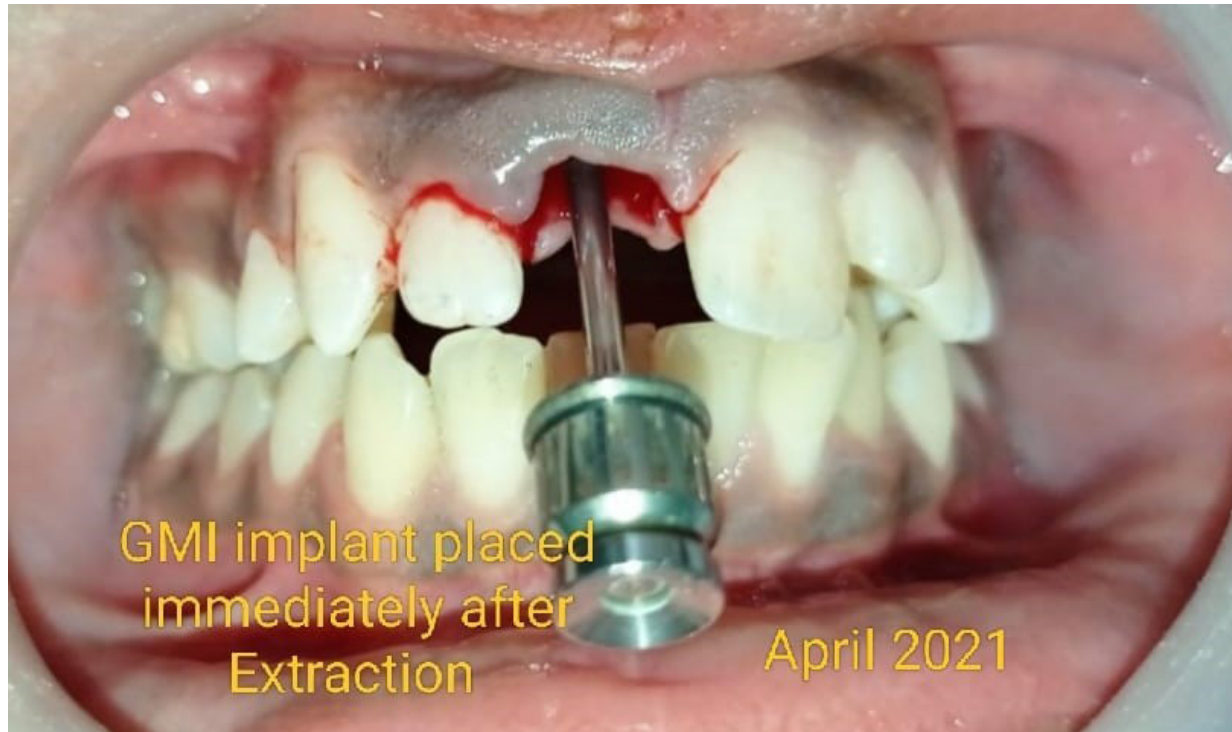Dr. Raj Kumar Bansal
India

In the bottom-left corner, there are two overlapping curved shapes. The outer one is a light teal color, and the inner one is a lighter blue color, both curving towards the bottom-left corner.

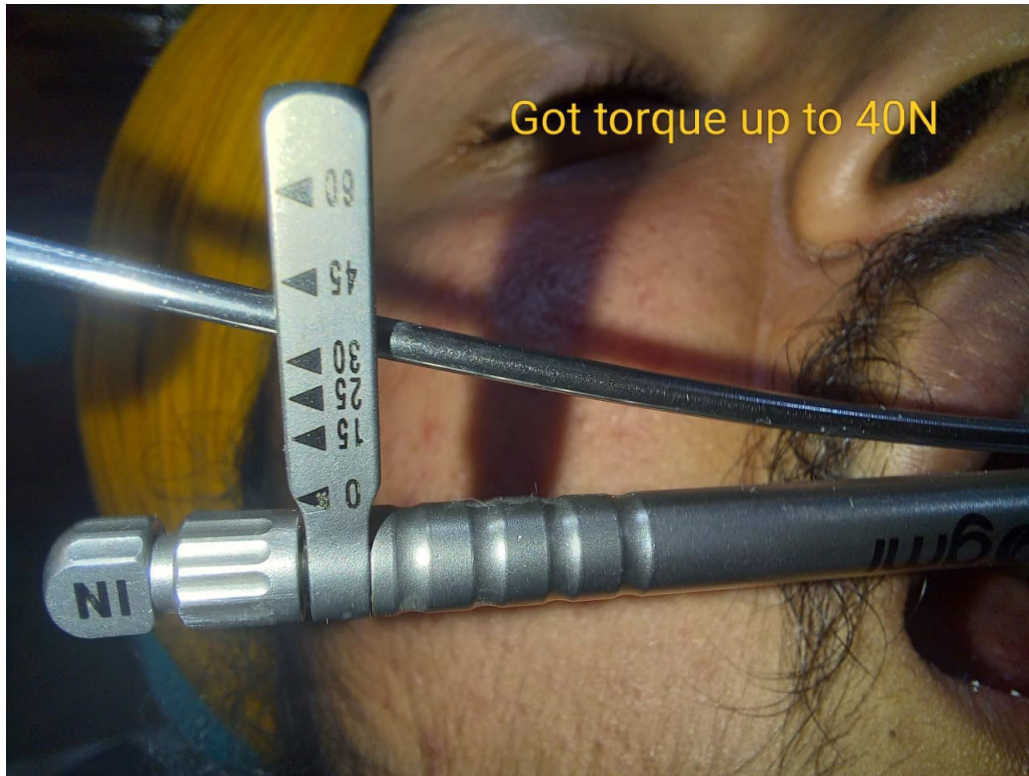Pre-operative condition - 18-years-old patient



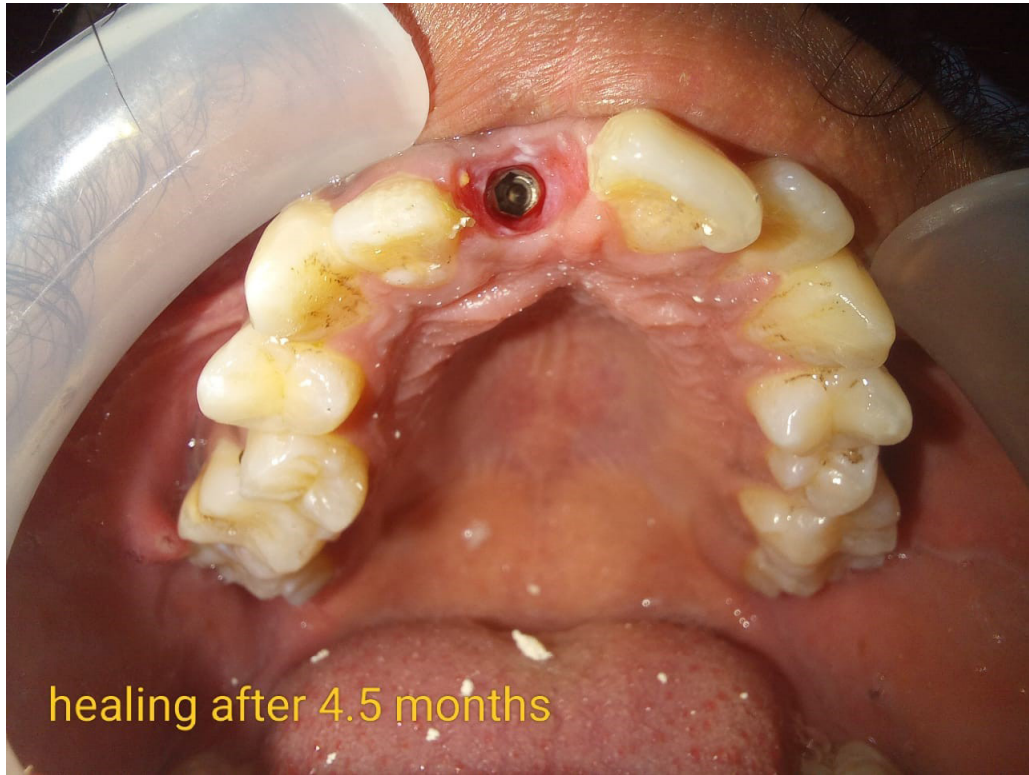
GMI Frontier implant placement



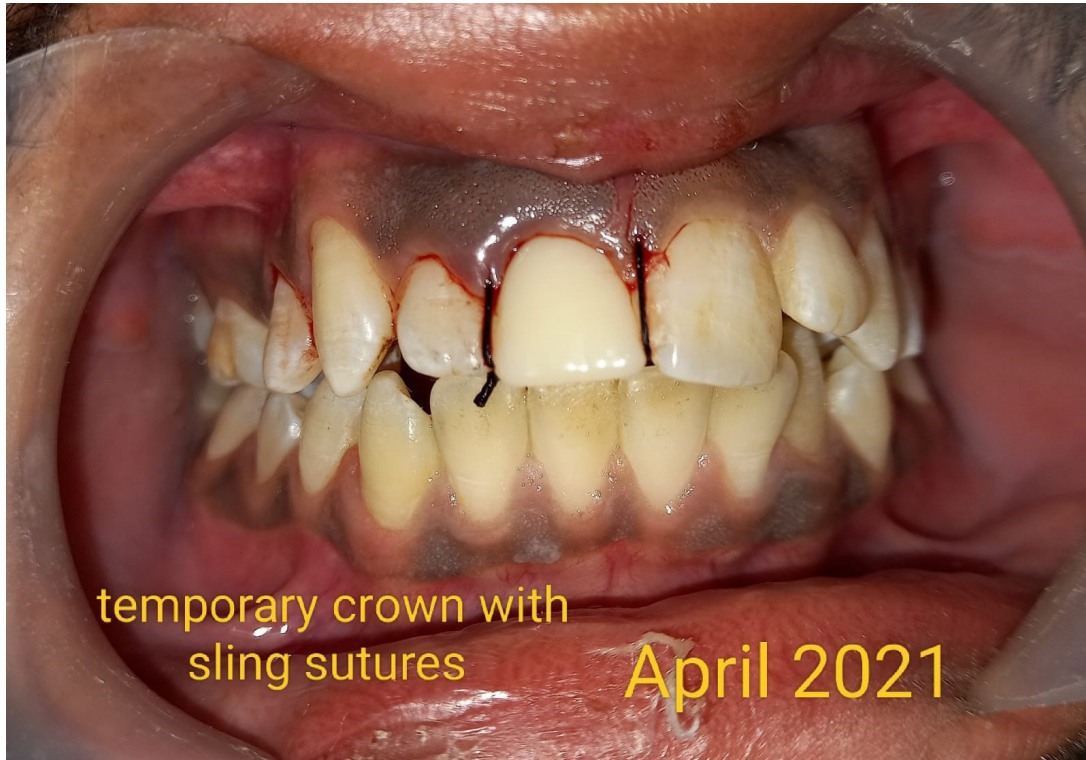Tightening with TI ratchet wrench



Healing after 4.5 months



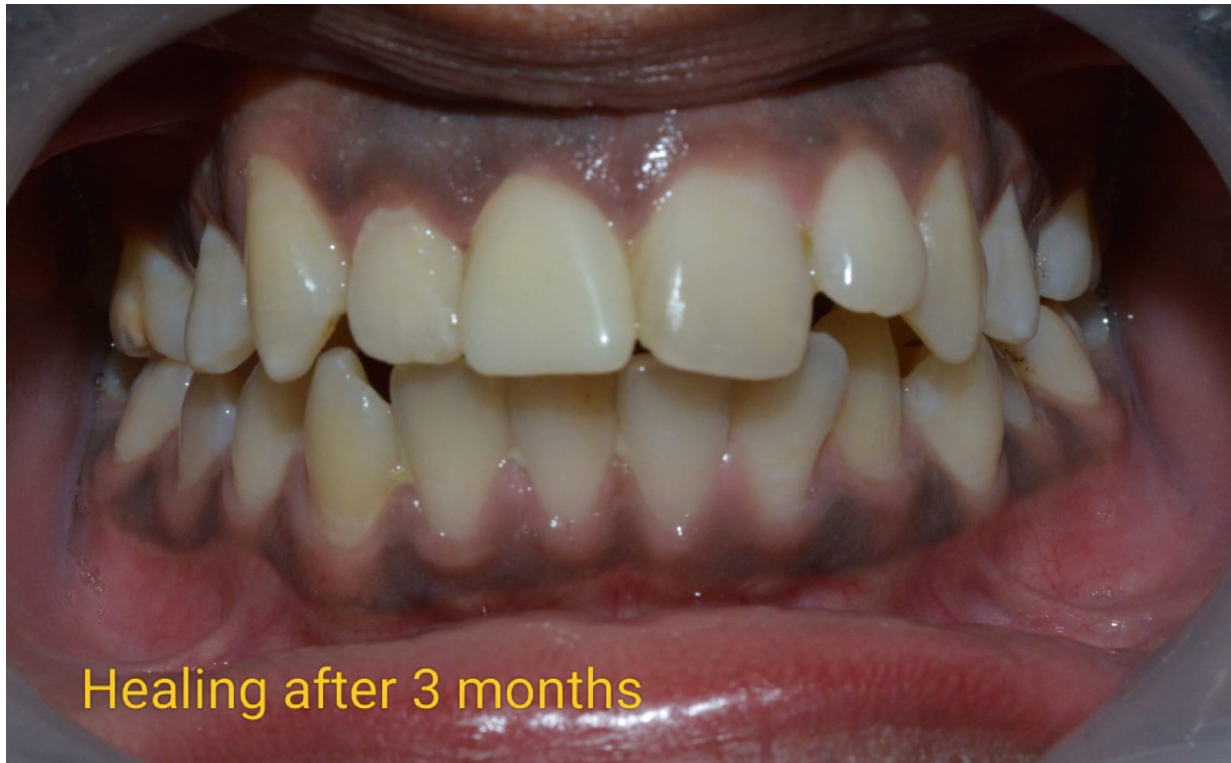Temporary crown



temporary crown with
sling sutures

April 2021

Healing after 3 months

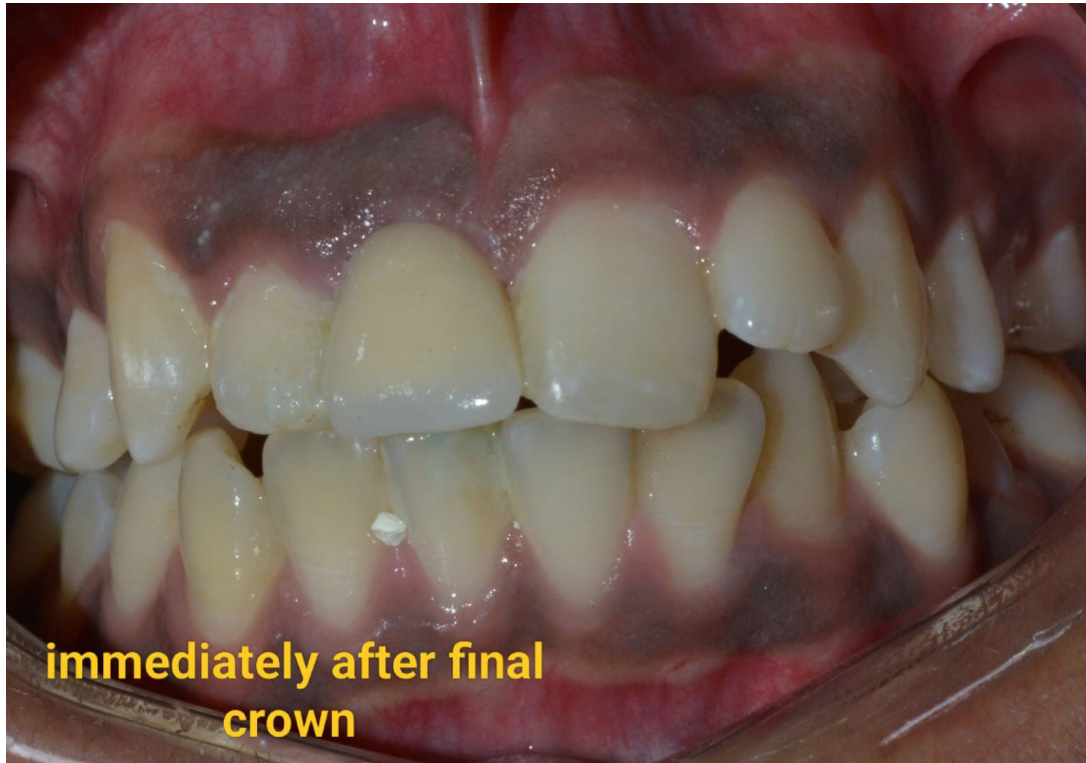

Screw-retained prosthesis

**screw retained
prosthesis given**



Immediately after final crown



After 4 years

