

.....

# FULL ARCH IMPLANT REHABILITATION USING GMI IMPLANTS

.....

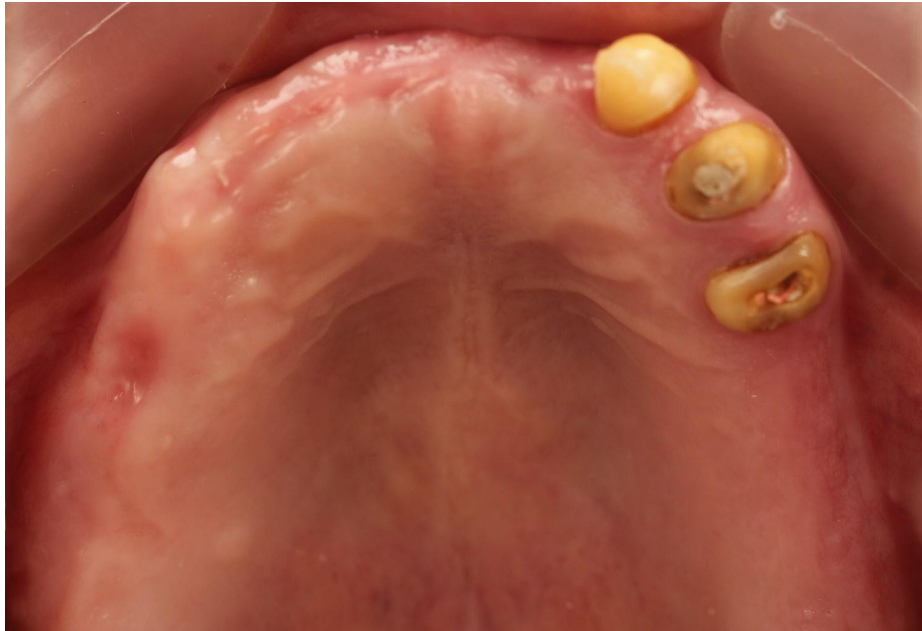Dr. Vijita Mehta  
India

In the bottom-left corner, there are two overlapping curved shapes. The outer one is a light teal color, and the inner one is a lighter blue color, both curving towards the bottom right.

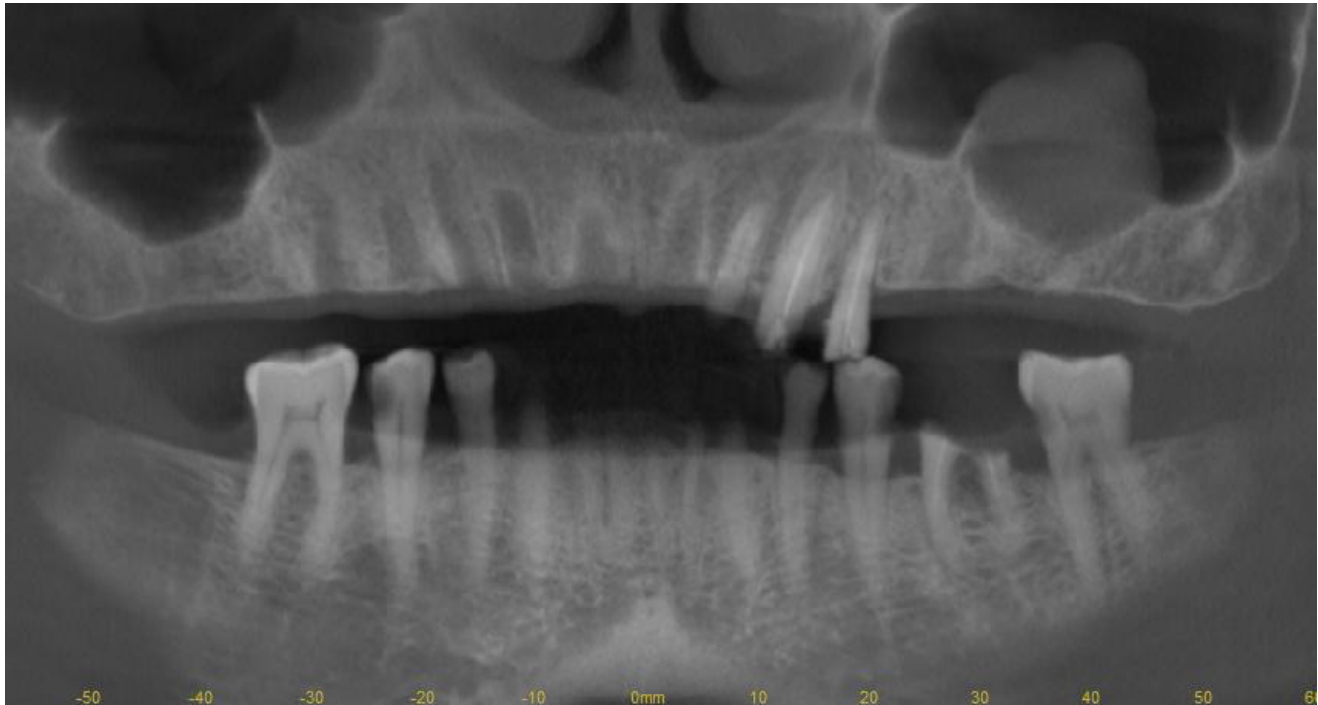
## Pre-operative condition

---

Patient complains of missing teeth in upper 12, 14, 16, 25, 26 extracted 22, 23, 24 region and wants a permanent solution. After investigations and diagnosis, implant was advised followed by crown.

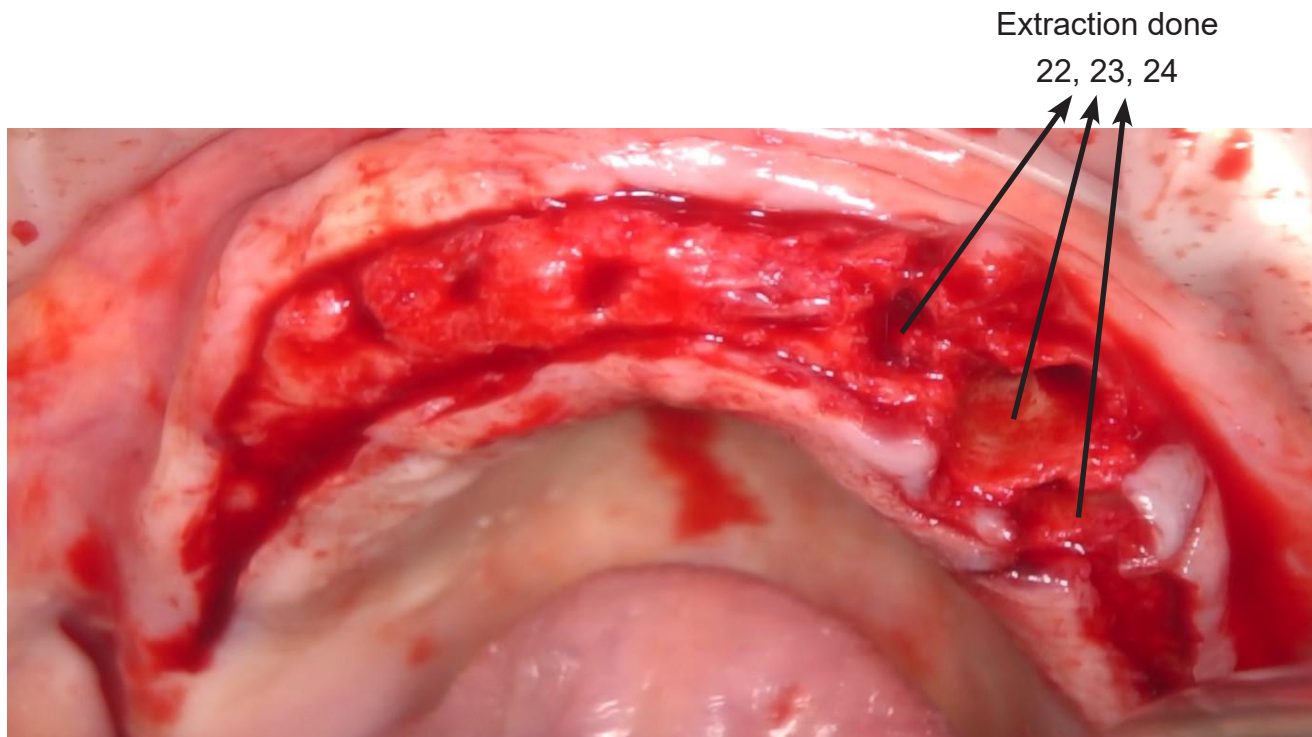


w.r.t. 12, 14, 16, 22, 23, 25, 26



w.r.t. 45

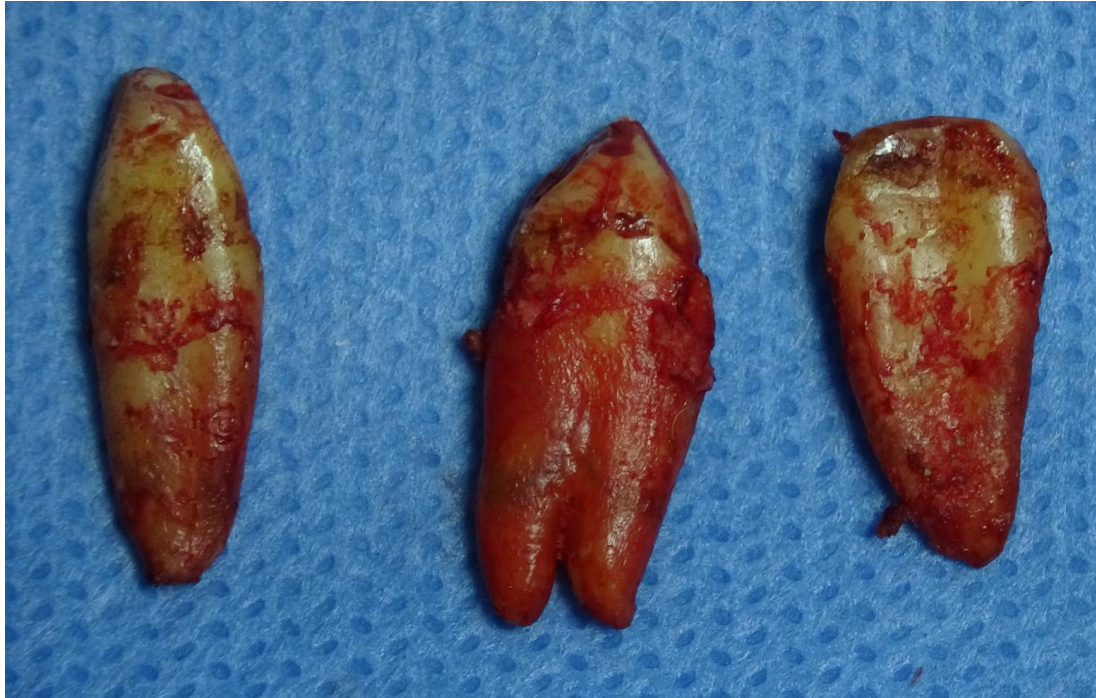## Flap raised



w.r.t. 12, 14, 16, 22, 23, 25, 26

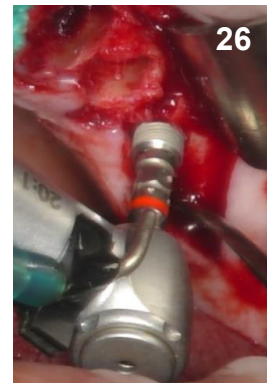
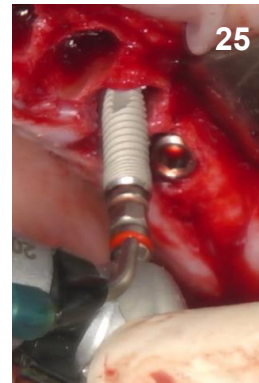
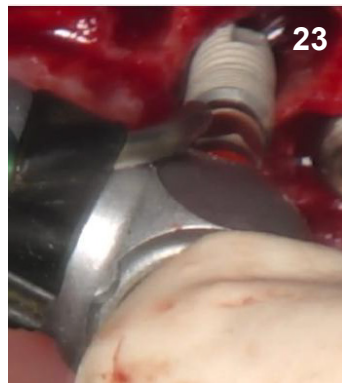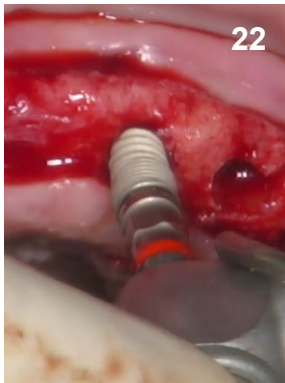
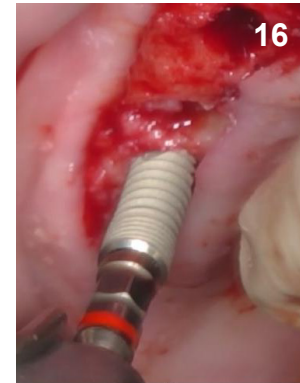
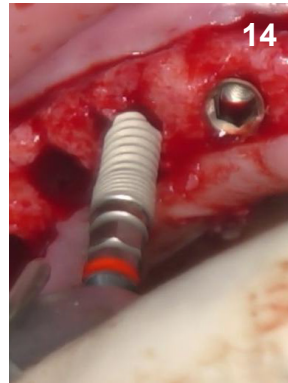
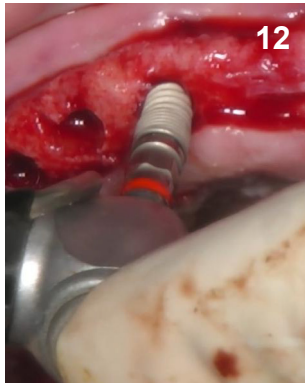
## Extracted tooth

---



w.r.t. 23, 23, 24

## Implant being placed

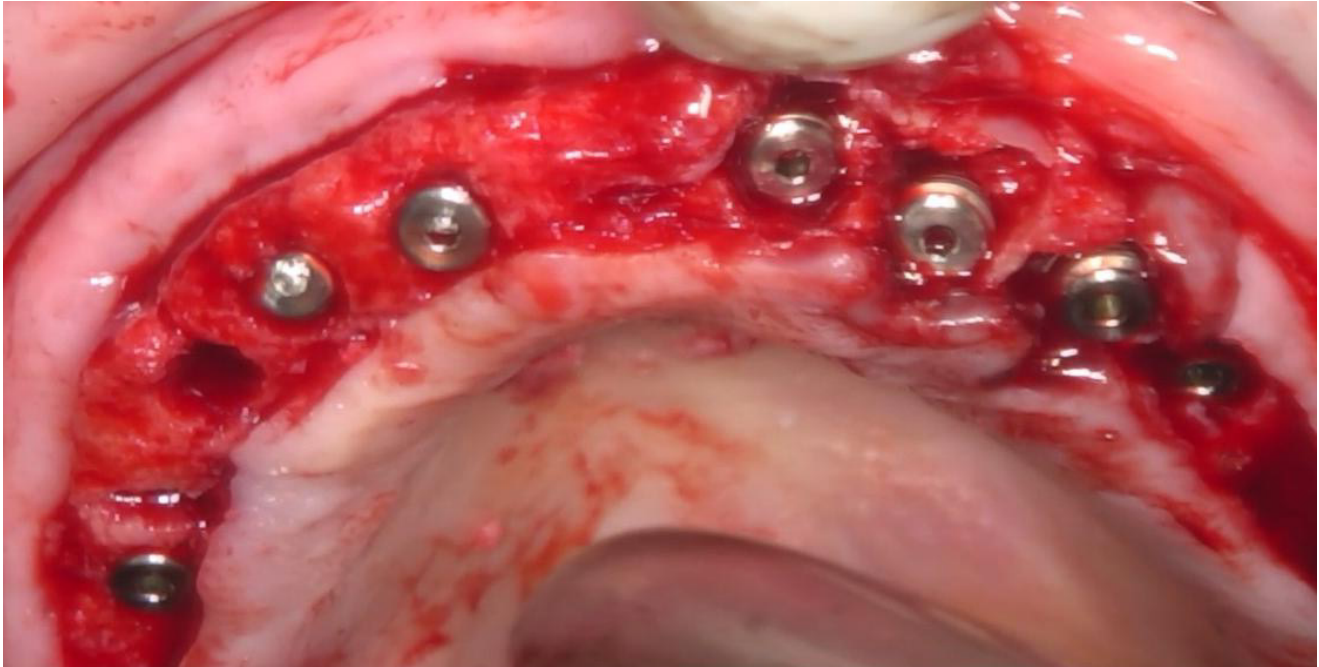

w.r.t. 12, 14, 16, 22, 23, 25, 26



## Cover screw placed

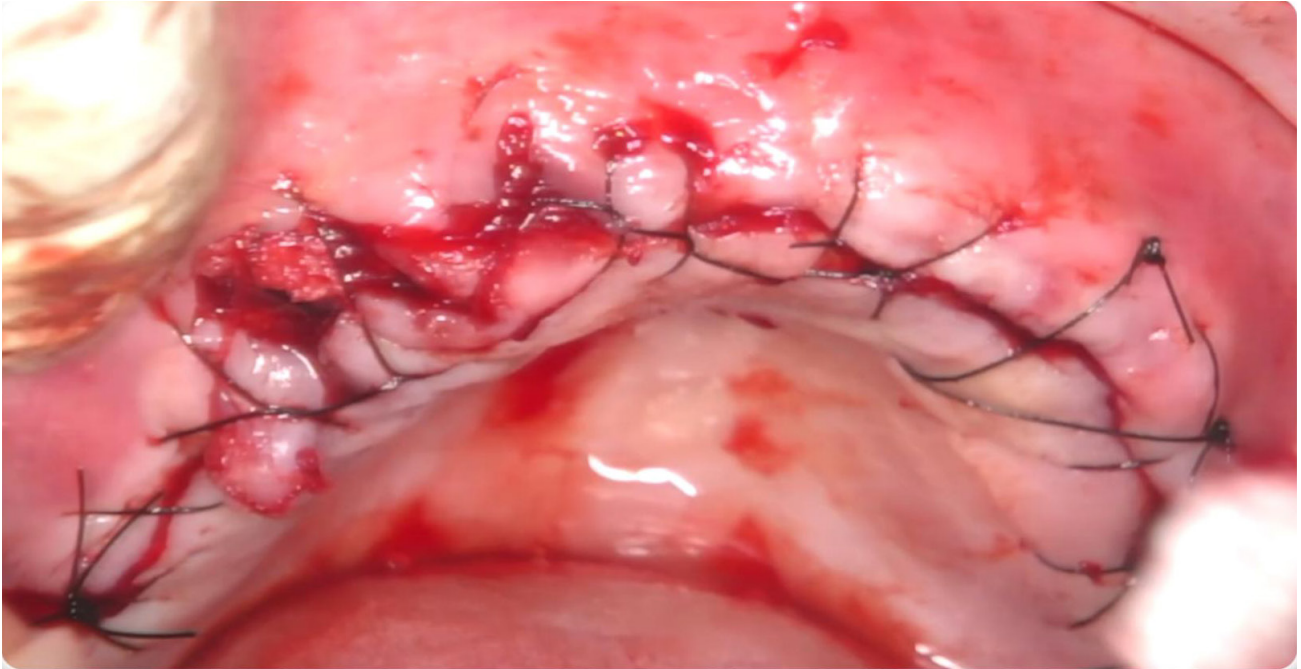
---



w.r.t. 12, 14, 16, 22, 23, 25, 26

## Suturing done

---

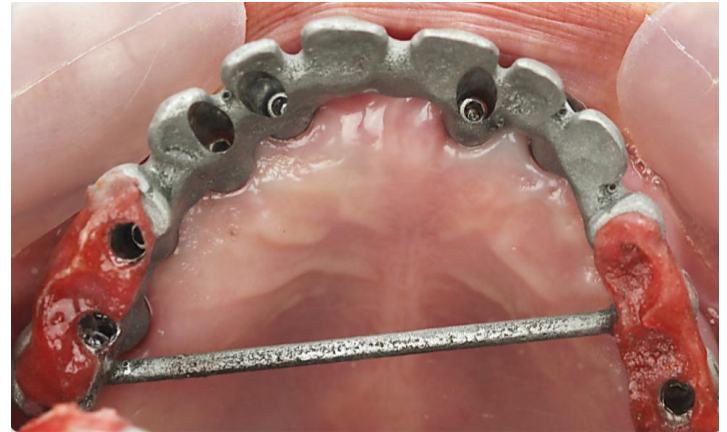
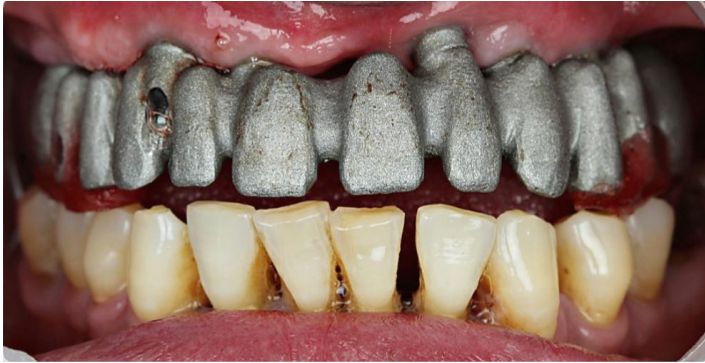
w.r.t. 12, 14, 16, 22, 23, 25, 26



## Metal trail

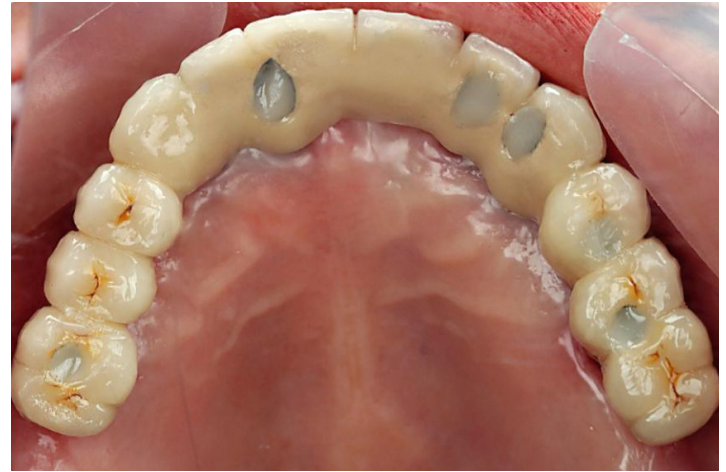
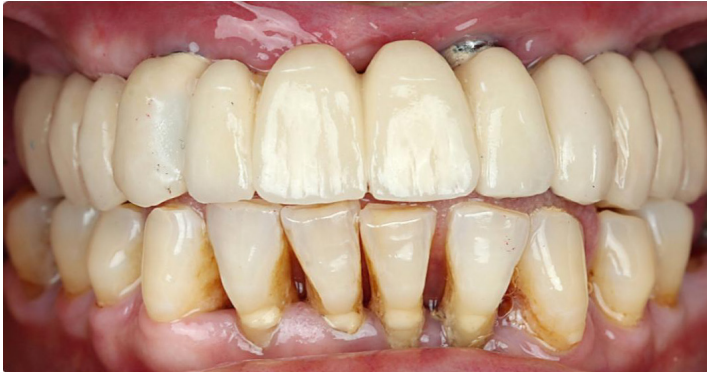---



w.r.t. 12, 14, 16, 22, 23, 25, 26

## Post-operative pictures

---

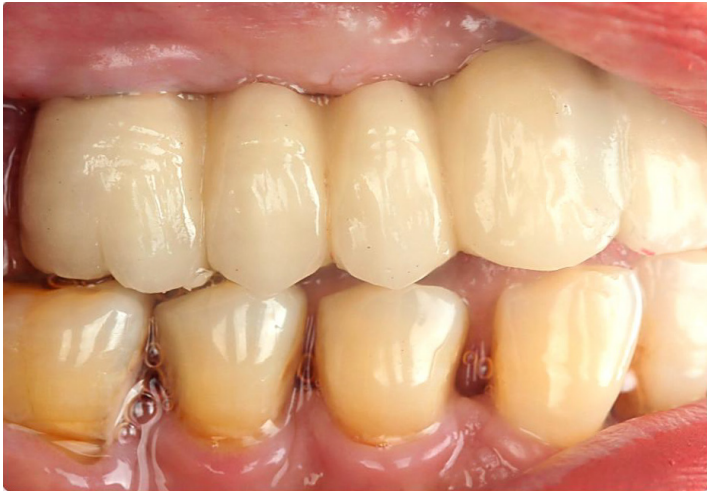

w.r.t. 12, 14, 16, 22, 23, 25, 26

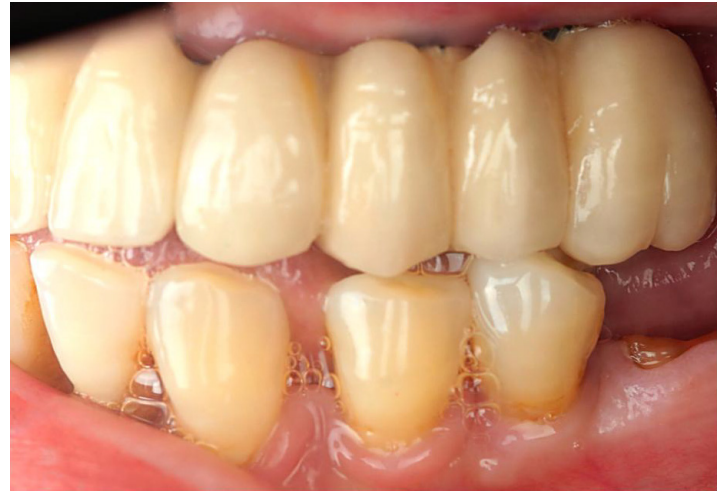## Post-operative pictures

---

Right



Left

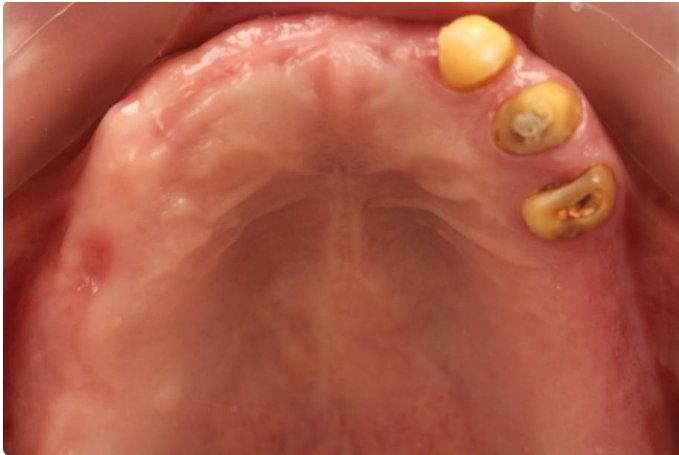

w.r.t. 12, 14, 16, 22, 23, 25, 26

## Comparison of pictures

---

Pre-operative picture



Post-operative picture



